

Diagnosis, Classification, and Frequency of C-Shaped Canals in Mandibular Second Molars in the Lebanese Population

Gaby Y. Haddad, DCD, DESE, Walid B. Nehme, DCD, DESE, and Hani F. Ounsi, DCD, DESE

C-shaped canals are mostly found in mandibular second molars. Studies have shown that frequency ranges from 2.7 to 31%. This study was undertaken to provide further knowledge of the distribution of such canal anatomy, by determining the frequency of C-shaped canals in a sample representing the Lebanese population. Ninety-four mandibular second molars with scheduled endodontic treatment were examined over a 1-yr period. Of the 94 treated molars, 18 exhibited C-shaped canals that would represent 19.1% of the sample. The geographical position of Lebanon could represent an explanation for this phenomenon.

C-shaped canals are mostly found in mandibular second molars (1). Their main anatomical feature is the presence of a fin connecting root canals (2) (Fig. 1). A C-shaped canal appears when fusion either on the buccal or lingual aspect of the tooth between distal and mesial roots occurs. This fusion remains irregular, and the two roots stay connected by an interradicular ribbon (2, 3). The pulp chamber has a single ribbon-shaped orifice with a 180° arc from the distal to mesial canal (4). The floor of the pulp chamber is deep and has an unusual anatomical appearance (3).

Mandibular second molars with C-shaped canals present many variations in canal configuration (5, 6). Knowing this anatomy enhances chances of successful treatment. The early recognition of these configurations allows one to better clean, shape, and obturate the root canal system (7). Preoperative radiographs show very close or fused roots. They sometimes even show the image of two distinct roots. This happens when the fin is very thin and thus not visible on the X-ray (2). Radiographs taken while probing the root canal system may suggest such anatomy. They can reveal two characteristics: instruments tend to converge at the apex (7, 8) and some instruments will appear clinically and radiographically to perforate the furcation (2, 5) (Fig. 2).

Text books of endodontics state that the C-shaped canal is not uncommon (9). This is confirmed by studies in which frequency ranged from 2.7 to 8% (1, 10). Although it is not specifically stated, these figures appear to relate to teeth of Caucasoid origin:

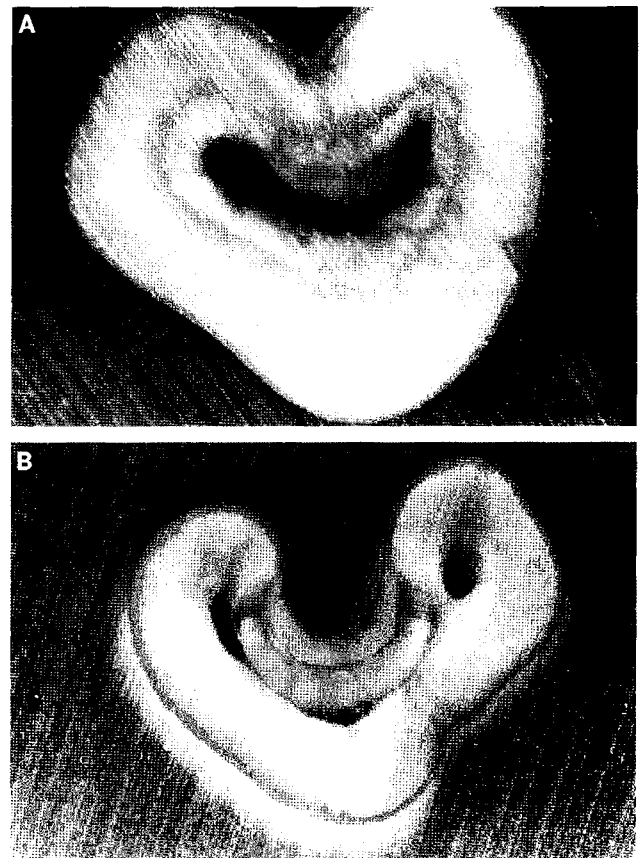


FIG 1. Cross-sections with magnification $\times 9$. (A) Through the floor of the chamber, it shows a C-shaped orifice that is formed from three root canals connected by a fin. (B) At the apical root level, the C-shape becomes more pronounced with the appearance of dentin separating three distinct canals.

investigations conducted on Japanese (11) and Chinese (6, 12) showed a high incidence of C-shaped canals (31.5%). It has thus been established that this particular anatomy is more frequent in Asians than in other racial groups (13). No data seems to be available as to the incidence of this canal configuration in the Middle East region.

This study was undertaken to provide further knowledge of the distribution of such canal anatomy, to establish a classification for

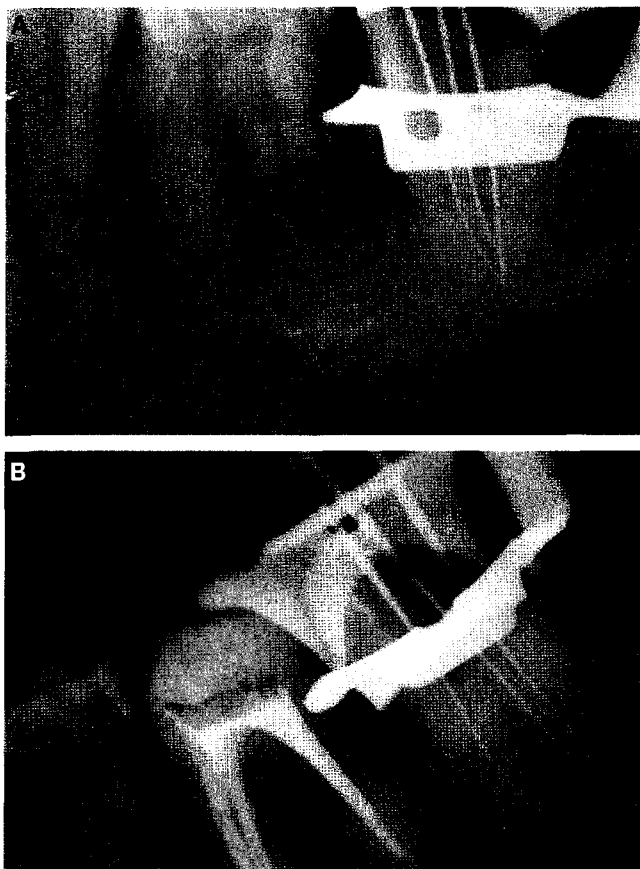


FIG 2. Radiograph with files to working length. (A) Instruments tend to converge at the apex. (B) Some instruments seem to perforate the furcation.

the most common configurations, and to determine the frequency of C-shaped canals in a sample representing the Lebanese population.

MATERIALS AND METHODS

Ninety-four mandibular second molars with scheduled endodontic treatment were examined over a 1-yr period in the Endodontic Department (Saint Joseph University, Beirut). C-shaped canals were detected and counted. Two detection procedures, radiography and clinical examination, were used. Two preoperative radiographs were taken: one with a 90° angulation to the tooth in a buccolingual direction and another at a mesial angle of ~20° to allow better visualization of the buccolingual anatomy. The radiographs were examined on a viewer using a peripheral block and a ×6 aspheric magnifying lens. The number and position of root canals were noted. Two postoperative radiographs using the same incidence were taken to confirm canal configuration.

Clinical investigation was done by scrutinizing the pulp chamber and canal entrance. While probing root canals with a #10 K-file (Maillefer, Baillaigues, Switzerland), radiographs were taken to confirm canal morphology.

Once C-shaped anatomy was recognized, teeth were classified using a Melton-like (5) classification pattern of three categories:

- Category I: continuous C-shaped canal running from the pulp chamber to the apex (Fig. 3)

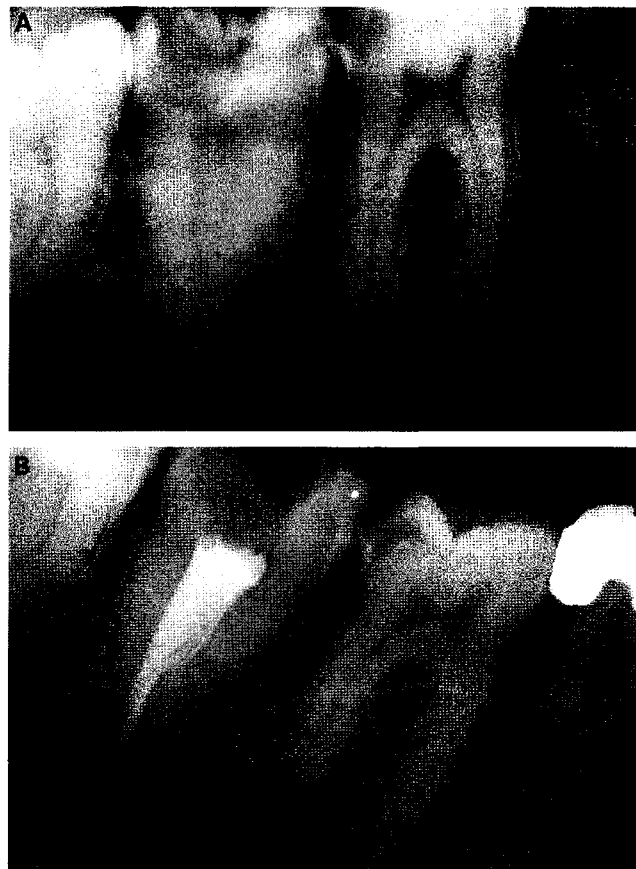


FIG 3. Category I. (A) Preoperative radiograph of the second molar showing fused roots. (B) True C-shaped canal filled with vertical condensation of warm gutta-percha.

- Category II: semicolon orifice in which dentin separates a C-shaped canal from one mesial distinct canal (Fig. 4)
- Category III: C-shaped orifice with two or more discrete and separate canals (Fig. 5).

RESULTS

Of the 94 treated molars, 18 exhibited C-shaped canals (19.1% of the sample). Only one molar presented a continuous C-shaped canal, and 13 had a semicolon shape with a mesial canal located on the buccal or lingual side (depending on where the fusion occurred). In many instances, this canal swung back and merged with the distal canal, thus yielding a single foramen; in the other cases, it remained distinct with its own portal of exit. The remaining four were considered as category III, among those, two were category I in the coronal third, category II at midroot, and then category I in the apical part. Two showed, respectively, two and three separate canals.

DISCUSSION

Cooke and Cox (1) stated that it was impossible to diagnose C-shaped canals on the preoperative radiograph. In this study, almost all preoperative radiographs showed common characteristics. These characteristics formed a typical image that allowed prediction of the existence of this anatomical condition. In fact,

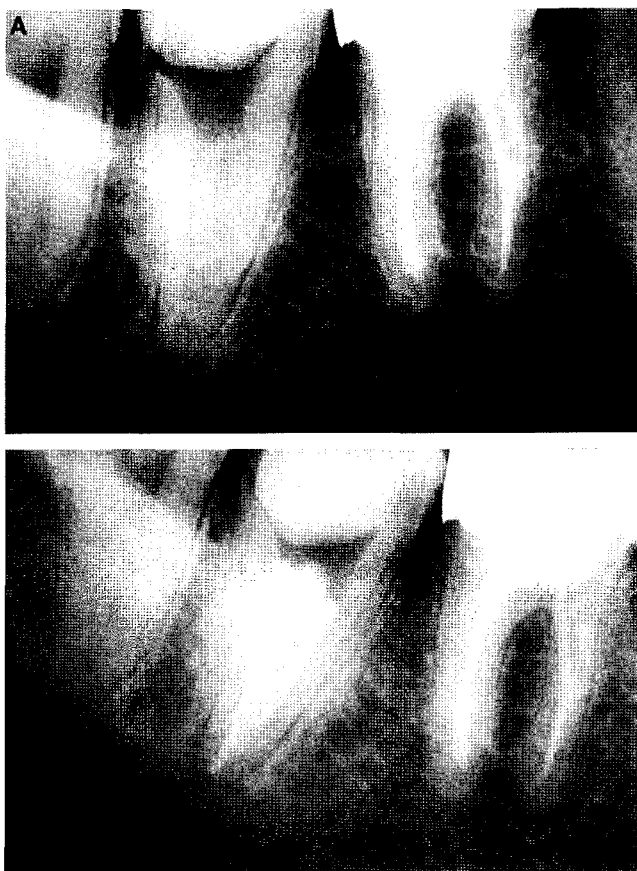


FIG 4. Category II. (A) Preoperative radiograph showing a radicular fusion, a large distal canal, a narrow mesial canal, and a blurred image of a third canal in between. (B) Postoperative radiograph. Note the presence of dentin separating a mesial canal from the rest of the C-shaped canal.

most radiographs revealed radicular fusion or proximity, a large distal canal, a narrow mesial canal, and a blurred image of a third canal in between (Fig. 4A). These radiographs were seen for teeth in category II, the most frequent. In some cases though, diagnosis was uncertain and clinical examination during the endodontic operative procedure was necessary.

Weine et al. (10) advised placing files in the canals to determine canal configuration of the mandibular second molar. However, using a radiograph showing files set to the canal terminus to diagnose and to determine canal morphology may not give the expected results. In some instances, it may be difficult to distinguish between a C-shaped canal and a mandibular second molar with single or three canals joining apically. Thus, it was necessary to confirm the diagnosis by exploring the access cavity. Two types of root canal orifices were observed in this study:

- A unique C-shaped orifice located either on buccal or lingual aspect of the floor, extended from the usual location of the distal canal to the location of the mesial canals (Fig. 6).
- Two orifices: a C-shaped orifice extending from distal to mesiobuccal in a buccal position separated with dentin from an independent mesiolingual orifice, or from distal to mesiolingual in a lingual position with an independent mesiobuccal orifice (Fig. 7).

True C-shaped canals with a single swath of canal are the exception rather than the rule (14). Yang et al. (6) found it to be the

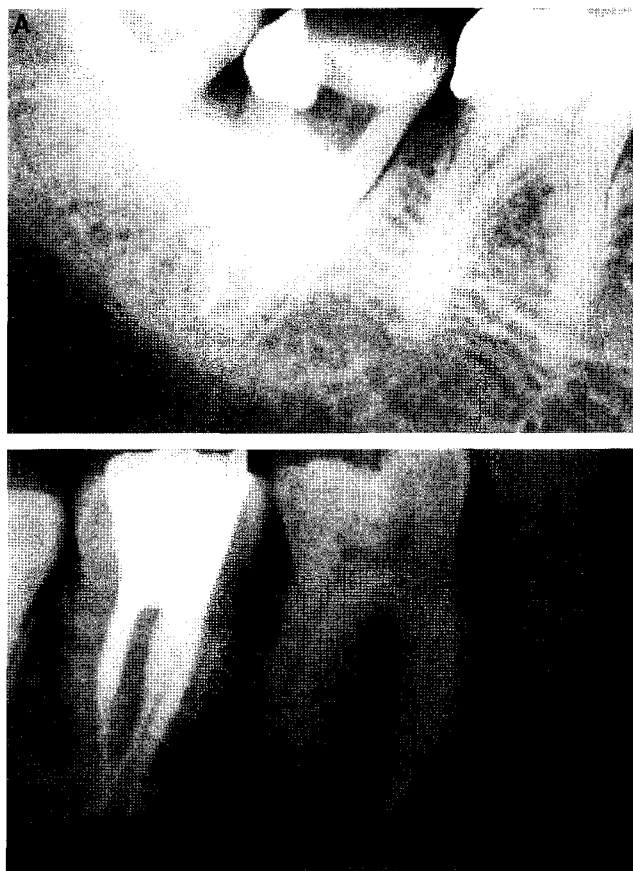


FIG 5. Category III. (A) With two separate canals. (B) With three separate canals.

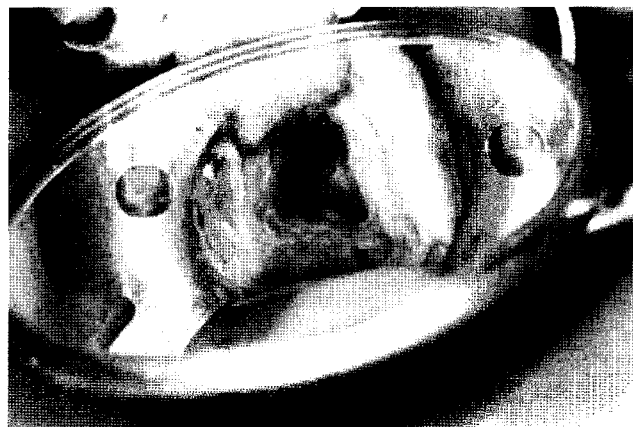

FIG 6. C-shaped chamber floor showing a C-shaped orifice located on the buccal aspect of the floor, extending from the usual location of the distal canal to the location of the mesiolingual canal.

less frequent configuration (7.4%). Manning (13) found that, among 19 teeth, only three true C-shapes that represent ~10%. In the present study, using roughly the same number of teeth, only one exhibited this form, making it even more exceptional.

Category II in this study was most frequent, agreeing with the results of Yang et al. (6). In this category, as described by Cohen and Burns (4), distinct canals were located on the mesiobuccal or mesiolingual aspect of the tooth, depending on where the radicular fusion occurred. Apically, this canal could merge to the C-shaped canal or remain distinct with its own portal of exit. In many cases,

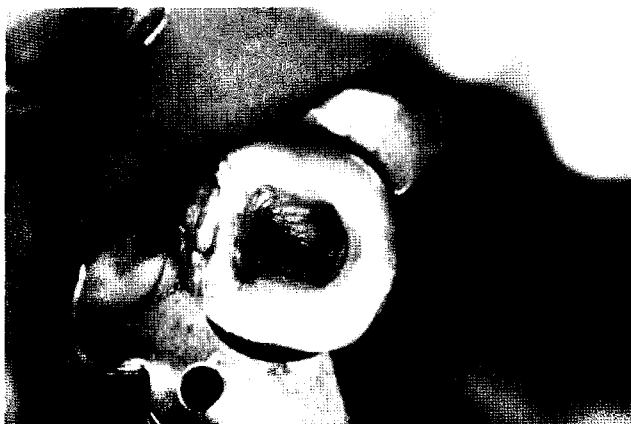

FIG 7. C-shaped chamber floor showing two orifices: a C-shaped orifice extending from the distal to mesiobuccal canal in a buccal position, and an independent mesiolingual orifice in a usual position.

its length was found to be shorter than the rest of the C-shaped canal.

In this study, all patients showing category III configuration >50 yr of age. This confirms Manning's observation of canal anatomy changes in C-shaped roots as a result of age-related deposition of dentin, thus forming separate canals. He also found that category III with three canals occurred most frequently. Unlike Manning (13), category III with three canals was a less frequent form in this study.

Melton et al. (5) reported that the C-shaped canal could change configuration at different levels. This was particularly true in all category III canals.

The 19.14% frequency obtained in this investigation is between the 31.5% frequency reported by Yang et al. (6) and the 8%

frequency reported by Cooke and Cox (1). The geographical position of Lebanon in particular and the Middle East in general (approximately half-way between the Far East and North America) may be the explanation for this phenomenon. Further studies would be necessary to confirm this theory.

Drs. Haddad, Nehme, and Ounsi are affiliated with Saint Joseph University, Beirut, Lebanon. Address requests for reprints to Dr. Gaby Y. Haddad, P.O. Box 14-6652, Beirut, Lebanon.

References

1. Cooke HG, Cox FL. C-shaped canal configurations in mandibular molars. *J Am Dent Assoc* 1979;99:836-9.
2. Barril I, Cochet JY, Ricci C. Le traitement des canaux présentant une configuration dite en "C." *Rev Fran Endod* 1989;8:47-58.
3. Barnett F. Mandibular molar with C-shaped canal. *Endod Dent Traumatol* 1986;2:79-81.
4. Cohen S, Burns R. *Pathways of the pulp*. 5th ed. St. Louis: Mosby, 1991:156.
5. Melton DC, Krell KV, Fuller MW. Anatomical and histological features of C-shaped canals in mandibular second molars. *J Endodon* 1991;17:384-8.
6. Yang ZP, Yang SF, Lin YL. C-shaped root canals in mandibular second molars in Chinese population. *Endod Dent Traumatol* 1988;4:160-3.
7. Rice RT, Gilbert BO. An unusual canal configuration in mandibular first molar. *J Endodon* 1987;13:513-5.
8. Machtou P. *Endodontie clinique*. Paris: Cdp, 1993:50-2.
9. Walton R, Torabinejad M. *Principles and practice of endodontics*. 2nd ed. Philadelphia: WB Saunders Co., 1996:177-8.
10. Weine FS, Pasiewicz RA, Rice RT. Canal configuration of the mandibular second molar using a clinically oriented in vitro method. *J Endodon* 1988;14:207-13.
11. Kotoku K. Morphological studies on the roots of the Japanese mandibular second molars. *Shikwa Gakuho* 1985;85:43-64.
12. Walker RT. Root form and canal anatomy of mandibular second molars in southern Chinese population. *J Endodon* 1988;14:325-9.
13. Manning SA. Root canal anatomy of mandibular second molars. Part II. C-shaped canals. *Int Endod J* 1990;23:40-5.
14. Cohen S, Burns R. *Pathways of the pulp*. 6th ed. St. Louis: CV Mosby, 1994:164-5.