

CLINICAL AID

A New Approach for the Retrieval of Broken Instruments

Walid Nehme, DDS, DESE


The purpose of this article is to present a modified ultrasonic spreader and a new technique that are used for the retrieval of solid obstructions that can not be bypassed by conventional methods. The technique advocated and the instruments proposed are described. A clinical case is discussed to show the possibilities and limitations of both instrument and method.

Several methods and techniques are advocated for the removal of solid objects, such as silver points, fragments of an instrument, or posts. Accessible solid obstructions may be withdrawn from the canal by a variety of instruments, including forceps, pliers, or a Castroviejios needle holder (1-3). Sometimes mechanical interventions should be undertaken and sophisticated tools such as the Masserann endodontic kit (4) and the Endo Extractor (5) are recommended. Endodontic textbooks (6) advocate bypassing the obstruction before trying to retrieve it from the canal. It could be done manually by the use of one or multiple Hedstrom files (7), with automated devices such as the canal Finder System (8) or with ultrasonic devices (9-11). The purpose of this paper is to describe a modified ultrasonic tip and a new technique, which makes the retrieval of solid fragments more predictable.

MATERIALS AND METHODS

Instrumentation consists of a piezoelectric ultrasonic unit and an ultrasonic spreader (S04) by Satellec (France). The modifications suggested to the spreader concerns its taper and diameter. A separating disc (Speedy, Hollicer, France) is used to reduce the diameter at the tip to 0.20 to 0.25 mm at D1 and at D2 (16 mm from D1) to 0.5 to 0.6 mm. This will roughly make a taper 0.02 spreader. A small round bur (#2 of Maillefer, Ballaigues, Switzerland) is used to make a hole in the shank to allow irrigation (Fig. 1, *a* and *b*). The freshly cut spreader should be smoothed and all sharp angles eliminated to prevent any potential for cutting by the lateral sides. Additional modified instruments are used, such as Gates-Glidden (GG) drills #1 and #2 sectioned at their maximum cross-

a



b




FIG 1. (a) Ultrasonic tips SO-4 (left) and modified spreader (right). (b) Straight view showing the difference in the taper and the hole in the shank.

sectional diameter to obtain a predictable caliber (GG1 = 0.5 mm, GG2 = 70 mm) (12). A #10 file and 25 mm long shortened by (2 to 3 mm) will have a sharp edge at the working end and a suitable rigidity (13).

This technique is applied whenever bypassing the obstruction is impossible. It could be divided into three steps. *Step 1:* The clinician should create sufficient space coronal to the obstruction. This is accomplished by serial use of files and GG drills. Files are

used to create sufficient space so GG drills can be safely used. GG drills are used serially from small to large, with each larger drill stepped out of the canal to enlarge the accessible portion. Then, depending on obstruction location and canal anatomy, a modified GG1 and sometimes a GG2 are used in approximation to the obstruction to create greater access lateral to the obstruction. The objective of this step is to eliminate all obstructing materials and even dentin walls that would hold back the fragment from coming out of the canal, and to provide a straight-line access to the obstruction. *Step 2:* One should expose the coronal end of the fragment with the shortened #10 file. Picking at the dentin with this file can be accomplished until the tip of the instrument is free of dentin. If a complete exposure is impossible, a moderate path of 0.5 to 1 mm could be sufficient. Solvents should be used if the obstruction is cemented or surrounded by obturation materials. R.C. Prep and sodium hypochlorite are usually more appropriate in tight and calcified canals free of obturation materials. Radiographs should be taken to make sure that the file is beside the obstruction and not in a wrong direction. The space created is then enlarged respectively with hand files #15, #20, and #25 to accept the diameter of the modified tip. *Step 3:* The ultrasonic spreader is introduced into this space next to the exposed part of the obstruction and activated for 1 or 2 min. It should be handled with a light touch and always kept in close contact with the exposed tip. Neither push-pull movement nor excessive force should be applied, because the objective is only to transmit vibration to the metallic obstruction and dislodge it. This maneuver can be repeated several times until the canal space is cleared. The first and second steps are time-consuming and may need 10 to 25 min, depending on canal configuration and instrument location, but the third step is relatively rapid usually taking no more than 2 to 5 min. At this stage, the only irrigant used is water, because it cleans the canal of debris and acts as a conducting medium for ultrasonic energy. But, the most important thing is that the flood of water will carry the loosened fragment out of the canal. This technique has been used for almost 2 yr, and 22 clinical cases have been documented. Only in two cases has this method failed. In the first case, the broken file was located beyond a sharp curve. Even though we managed to expose the tip with hand files, we failed to deliver the vibrations to the broken file tip because a straight access could not be achieved. In the second case, a #10 file was blocked in an apical curve of a distolingual canal of a second mandibular molar. In this case, the method failed because we could not expose the tip of the broken file. But, in the other 20 cases, metallic obstructions were eliminated. A case that shows retrieval follows.

CASE REPORT

A 30-yr-old male was referred for the retreatment of mandibular right first molar. Radiographs showed a broken file in the mesial root with an apical lesion and an underfilled distal canal (Fig. 2). After the crown was removed, tooth isolation and an access cavity were accomplished. Xylol was used to soften the old filling material, which was totally eliminated from distolingual and mesio-buccal canals and from the mesiolingual canal coronal to the broken instrument. A shortened #10 file was used to expose the end of the instrument, and the path was enlarged as described previously. Before using the modified spreader cotton pellets were placed over the other orifices so that the retrieved instrument would not enter another canal. The ultrasonic tip was placed in close contact with the remnant of the file for ~1 min. This activity

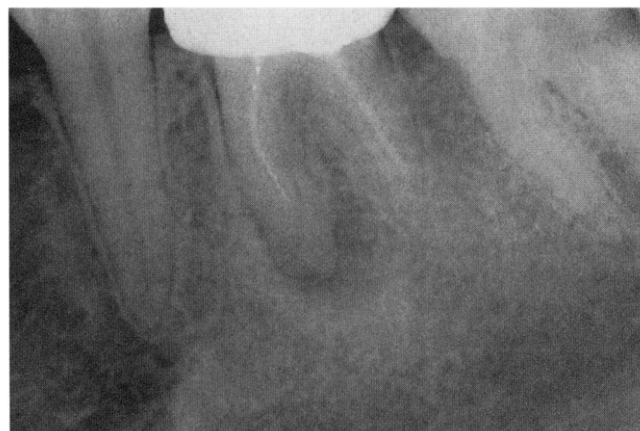

FIG 2. Preoperative radiograph of a mandibular right first molar demonstrates a mesial root with an apical pathology, a broken instrument at its middle third, and an underfilled distal canal.

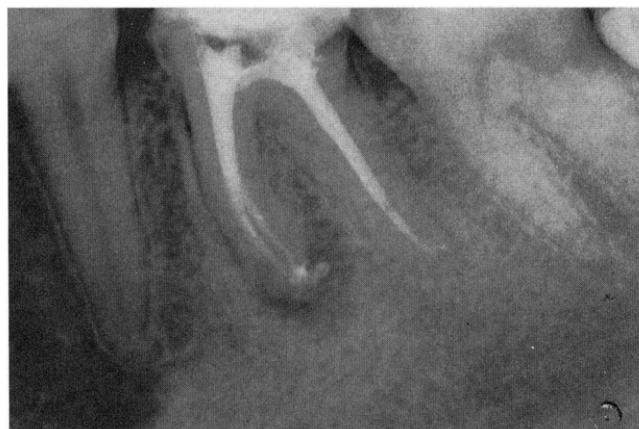

FIG 3. A postoperative radiograph reveals a densely packed root canal system.

typically works to unwind, loosen, and elevate the fragment into the previously enlarged canal. Afterward, endodontic procedures were completed, and the root canal system was packed with warm gutta-percha using the vertical condensation technique (Fig. 3).

DISCUSSION

The taper of the modified spreader conforms to ISO specifications and allows deeper penetration in the canal without excessive tooth structure loss while leaving sufficient space for instrument withdrawal. This is an advantage when compared with normal spreaders, where thickness at the middle and coronal thirds make deep penetration in root canals difficult. The major disadvantage of ultrasonic K-files is breakage (14). Therefore, the use of this modified spreader is helpful because it is as small as ultrasonic files #20 to #25, but much more resistant to fracture. Breakage may occur if this instrument is handled with excessive force, or if it is used to eliminate amalgam or hard setting pastes from root canals. Unlike ultrasonic files with cutting flutes, it has smooth sides, which means it will only be active at its tip where needed. Adding irrigation is an important modification. It will reduce overheating and create an irrigant stream that will carry the instrument out of the canal. The technique proposed is helpful each time an obstruction cannot be bypassed, and is safe and predictable when the

following conditions are respected. (a) Enlargement of the coronal part is indispensable. It straightens access to the obstruction, and creates a space large enough to accept at the same time the ultrasonic spreader and the obstructing obstacle on its way out of the canal. This is accomplished with minimal dentin loss using the modified GG drills, which allow immediate contact with the tip of the obstruction with a constant enlargement. (b) Determination of the exact location of the exposed obstruction is the second condition. In this technique, unlike others, where an operating microscope is used, we cannot see the obstruction. We have to feel it with hand files and confirm this sensation by radiographs. The length of the accessible portion of the canal is calculated with a #10 file and should be transferred to the insert so the vibration may be delivered at the exact location. Applying these vibrations elsewhere in the canal may cause transportation or perforation. Several authors (6, 15) have reported that applying the tip on the coronal part of an instrument could push it apically. This is true in cases where the obstruction can be bypassed. But, in the other cases, the instrument receiving vibrations will begin to vibrate by itself before loosening. We suppose that because it can not progress in apical direction, it will proceed to the only other available path, which is out of the canal. Therefore, applying vibration to the tip of the obstruction appears safe in these situations. This technique and this modified spreader would be of great help for clinicians working without a microscope. If they are aware of its limitations and apply it rigorously, it will enhance their ability to retrieve solid obstructions with confidence.

Dr. Nehme is a clinical assistant, Endodontic Department, St. Joseph University of Beirut, Beirut, Lebanon. Address requests for reprints to Dr. Walid Nehme, Space Center, New Jdeide Street, Jdeide, Beirut, Lebanon.

References

1. Nichols E. Endodontics. Bristol: J. Wright & Sons, 1967:227-9.
2. Fors UGH, Berg JO. A method for the removal of broken endodontic instruments from root canals. *J Endodon* 1983;9:156-9.
3. Weisman M. The removal of difficult silver cones. *J Endodon* 1983;9:210-1.
4. Masserann J. L'extraction des fragments de tenons intra radiculaires. *Actualites Odonto-stomatologiques* 1966;75:329-42.
5. Sprigs K, Gettleman B, Messer H. Evaluation of a new method for silver point removal. *J Endodon* 1990;16:335-8.
6. Adam S, Friedman S, Tamse A. Endodontic failures and re-treatment. In: *Pathways of the pulp*. 6th ed. Philadelphia: Mosby, 1994:690-727.
7. Ingle JI, Luebke RG, Walton RE, Zidell JD. Obturation of the radicular space. In: *Endodontics*. 2nd ed. Philadelphia: Lea & Febiger, 1996:269-71.
8. Hulsmann M. The removal of silver cones using different techniques. *Int Endod J* 1990;23:298-303.
9. Gaffney JL, Lehman JW, Miles MJ. Expanded use of ultrasonic scaler. *J Endodon* 1981;7:228-9.
10. Krell KV, Fuller MW, Scott GL. The conservative retrieval of silver cones in difficult cases. *J Endodon* 1984;10:269-73.
11. Nagai O, Tani N, Kayaba Y, Kodama S, Osada T. Ultrasonic removal of broken instrument in root canals. *Int Endod J* 1986;19:298-304.
12. Ruddle CJ. Micro-endodontic nonsurgical retreatment. *Dent Clin North Am* 1997;3:429-54.
13. Vianna EFF, Wencks C, Aun EC. Retreatment using a modified-tip instrument. *J Endodon* 1995;21:425-8.
14. Souyave LCJ, Inglis AT, Alcolay M. Removal of fracture endodontic instrument using ultrasonics. *Br Dent J* 1985;159:251-3.
15. Machtoo P. Silver cones and separated instruments retrieval. *Realites Cliniques* 1996;7:315-22.